

## Diffusion Tensor Imaging of Neurodevelopment in Adolescents and Young Adults

L. Snook<sup>1</sup>, L. Paulson<sup>1</sup>, D. Roy<sup>2</sup>, Y. A. Bhagat<sup>1</sup>, S. McCrea<sup>1</sup>, L. Phillips<sup>2</sup>, C. Beaulieu<sup>1</sup>

<sup>1</sup>Biomedical Engineering, University of Alberta, Edmonton, Alberta, Canada, <sup>2</sup>Education, University of Alberta, Edmonton, Alberta, Canada

**Introduction:** Developmental studies have shown the value of diffusion tensor imaging (DTI) providing more specific information about the widespread maturation of brain white matter than conventional T1- and T2-weighted MR imaging methods<sup>1,2</sup>. Increases in the anisotropy of water diffusion in white matter with age are attributed to the process of myelination and/or the continued organization and compaction of axons in the white matter tracts<sup>3</sup>. The purpose of this study was to focus on the changes in fractional anisotropy (FA) in 22 distinct brain regions including both deep and peripheral white and gray matter within a narrow adolescent age range (8 – 12 years), as well as a comparison of the diffusion characteristics in the children to a group of young adults (21 – 25 years). Correlative analysis of a broader set of brain regions on higher resolution images has led to observations of diffusion changes with neurodevelopment that have not been reported previously.

**Methods:** This study includes 32 children aged 8 – 12 years (average 11.1 ± 1.3) and 8 young adults aged 21 – 25 (average 24 ± 2) years. Healthy subjects were selected with no history of neurological injury or psychiatric disease. Subjects were scanned with a 1.5T Siemens Sonata scanner for approximately 26 minutes including anatomical imaging and DTI sequences. DTI used 3 mm thick slices with no gap, matrix of 128x128 zero filled to 256x256 resulting in a voxel size of 0.85 x 0.85 x 3.0 mm<sup>3</sup>, 40 contiguous slices for whole brain coverage, TE / TR of 88 ms / 6400 ms, b = 0 s/mm<sup>2</sup> and six sets with b = 1000 s/mm<sup>2</sup>. Regions-of-interest (ROIs) were manually placed on FA (Figure 1) and trace ADC maps in 22 specific areas of white matter (WM) and gray matter (GM). Where appropriate, ROIs were placed on left and right hemispheres and tested for significant differences between left and right. Two different analyses were performed. Analysis 1: Linear regression was performed on 8 – 12 year olds to measure diffusion trends within this narrow age range. Analysis 2: Regional group statistics was performed to compare the combined younger age group (8 – 12 years) to the older age group (21 – 25 years) using unpaired t-tests.

**Results and Discussion:** *Regression Analysis Between 8-12 yrs:* Within the 8 – 12 year age range, no left/right asymmetry was seen in FA except in the external capsule and the centrum semiovale, with FA greater on the left. Trace ADC decreased with age in all measured areas (p<0.05) except the genu of the corpus callosum, posterior limb of internal capsule, and cortical gray matter of some gyri. The most significant increases in FA between 8 – 12 years of age were seen in the head of the caudate nucleus (r=0.57, p<0.001, FA 0.11-0.20), genu of corpus callosum (r=0.54, p=0.002, FA 0.61-0.78), and splenium of corpus callosum (r=0.42, p=0.02, FA 0.70-0.83) (Figure 2). Significant differences of FA were also seen in the corona radiata (r=0.40, p=0.02), subcortical white matter of superior frontal gyrus (r=0.36, p=0.04), cortical gray matter of the superior frontal gyrus (r=0.35, p=0.05), and the putamen (r=0.35, p=0.05). *Group Analysis 8-12 yrs versus 21-25 yrs:* Significant decreases (p<0.05) were seen in trace ADC in 16 of the 22 regions. Differences in FA between the two age groups were less widespread but the changes were greater than for trace ADC. With the exception of the anterior limb of the internal capsule, most major white matter tracts like the corpus callosum did not demonstrate changes in FA from 8-12 to 21-25 years, but there were extensive FA increases of 23-27% in the deep gray matter structures (Table 1). Increases in FA were also observed in the subcortical white matter of the supra marginal gyrus (p=0.03, 9%) and the middle occipital gyrus (p=0.01, 12%) as well as cortical gray matter of the superior temporal gyrus (p<0.01, 22%). The DTI measurements imply regional differences in timing of brain maturation since some brain regions observed to show changes in FA between 8-12 years of age did not show changes at older ages of 21-25 years, and vice-versa.

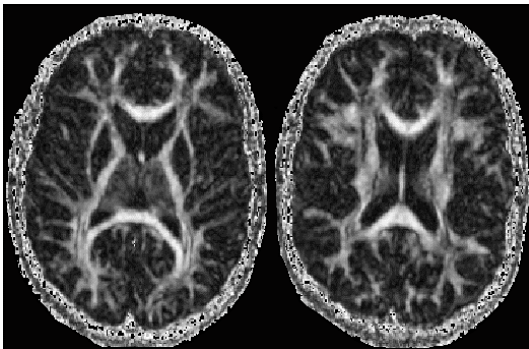


Figure 1: Fractional anisotropy maps in 11 yr old male.

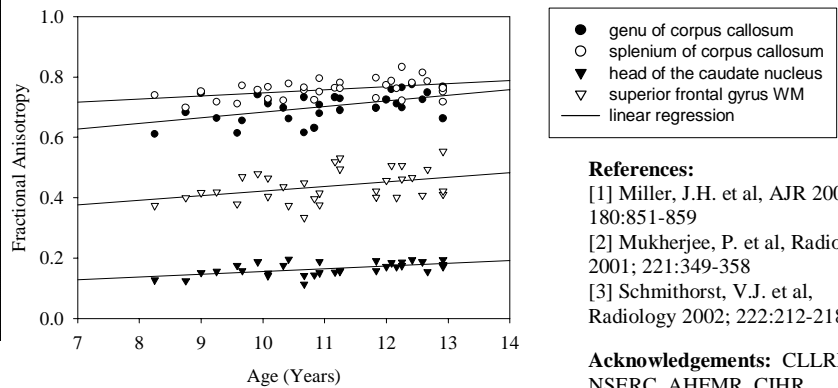


Figure 2: Trends of anisotropy from ages 8 - 12 years

**References:**

- [1] Miller, J.H. et al, AJR 2003; 180:851-859
- [2] Mukherjee, P. et al, Radiology 2001; 221:349-358
- [3] Schmithorst, V.J. et al, Radiology 2002; 222:212-218

**Acknowledgements:** CLLRNet, NSERC, AHFMR, CIHR

Region	Kids FA (N=32)	Young FA (N=8)	% Difference	Kids Trace ADC	Young Trace ADC	% Difference
	(8 - 12 years)	(21 - 25 years)		(8 - 12 years)	(21 - 25 years)	
	(mean ± SD)			(mean ± SD) 10-3 mm <sup>2</sup> /s		
Anterior Limb of IC	0.58 ± 0.04	0.63 ± 0.04	8*	0.74 ± 0.03	0.70 ± 0.01	-6*
Thalamus	0.29 ± 0.04	0.39 ± 0.03	25*	0.77 ± 0.03	0.73 ± 0.02	-5*
Globus Pallidus	0.25 ± 0.02	0.32 ± 0.03	23*	0.76 ± 0.02	0.73 ± 0.02	-5*
Putamen	0.15 ± 0.02	0.20 ± 0.02	27*	0.73 ± 0.02	0.70 ± 0.02	-5*
Caudate Nucleus	0.16 ± 0.02	0.23 ± 0.02	27*	0.73 ± 0.03	0.68 ± 0.02	-8*

Table 1: Fractional anisotropy in various brain regions for 8-12 year olds and 21-25 year olds (\* p < 0.05)