

Short communication

A functional magnetic resonance imaging study of the body schema using full human line-drawing figures in an on-line verbal naming and localization task of single body part words

Simon M. McCrea*

Department of Biomedical Engineering, Faculty of Medicine, University of Alberta, Edmonton, Alberta, Canada T6G 2V2

Received 6 December 2006; received in revised form 7 March 2007; accepted 13 March 2007

Available online 19 March 2007

Abstract

Naming and localization of individual body part words to a high-resolution line drawing of a full human figure was tested in a mixed-sex sample of nine right handed subjects. Activation within the superior medial left parietal cortex and bilateral dorsolateral cortex was consistent with involvement of the body schema which is a dynamic postural self-representation coding and combining sensory afference and motor efference inputs/outputs that is automatic and nonconscious. Additional activation of the left rostral occipitotemporal cortex was consistent with involvement of the neural correlates of the verbalizable body structural description that encodes semantic and categorical representations to animate objects such as full human figures. The results point to a highly distributed cortical representation for the encoding and manipulation of body part information and highlight the need for the incorporation of more ecologically valid measures of body schema coding in future functional neuroimaging studies. © 2007 Elsevier B.V. All rights reserved.

Keywords: Face encoding; Face recognition; Body part naming; Body schema; Body structural description; Body image; Autotopagnosia; Right–left disorientation; Finger agnosia

The group of disorders that involve disturbances of the body schema include: autotopagnosia, finger agnosia, phantoms, right–left disorientation, and perhaps visuomimetic apraxia for meaningless gestures [8]. In the transition from egocentric coordinates to extrapersonal spatially defined targets a series of automatic and nonconscious transformations takes place in which cells in Brodmann's areas seven and five convert retinotopic to head- to trunk- to shoulder- and arm-centered coordinates [12]. Awareness of one's own body requires vestibular, kinesthetic, tactile, and visual stimuli and complexes of these stimuli as perceptions and cognitive processes. Perhaps the most compelling argument for a mental body image are "phantoms" [14]. Such preliminary studies point towards the current lack of comprehensive conceptual frameworks in which to understand these uniquely human abilities.

Classically two variants of the body schema disruption have been identified in which the body schema is both completely or partially lesioned constituting autotopagnosia and finger agnosia, respectively [8]. Pick first described autotopagnosia (AT) in 1908 in which the primary features of the disorder was a loss of spatial knowledge about one's body [18]. It involves problems in pointing to body parts on verbal command and to imitation (i) on the patient's own body; (ii) on the examiner's body; (iii) or on a manikin or picture. Of the dozen or so recorded cases in which AT has been found without confounding language, general spatial localization, or dementia, it has been most often associated with early onset left parietal neoplastic lesions [8].

Finger agnosia in contrast involves difficulty in recognizing, identifying, and naming the fingers of the hand and was first described by Gerstmann [11]. Gerstmann's syndrome consists of finger agnosia, agraphia, acalculia, and right–left disorientation. Gerstmann attributed the neurological substrate to left angular gyrus lesions in the transition to the second occipital gyrus. More recent high-resolution CT and MRI, and virtual-lesioning studies have unequivocally demonstrated the four elements of

* Correspondence address: Department of Neuroophthalmology, University of British Columbia, 2500 Willow Street, Vancouver, British Columbia, Canada V5Z 3N9. Tel.: +1 604 875 4111x62929; fax: +1 604 875 4302.

E-mail address: smccrea@interchange.ubc.ca.

the syndrome in several well-described patients [8]. Gerstmann noted that all four of these symptoms require the “notion of finger sense” in the context of finger praxis, the decimal system, or right–left orientation’s common use of the hands.

Whereas AT involves the left parietal lobule finger agnosia occurs equally in patients with both left and right hemisphere lesions [13]. Recently a case of crossed AT was found in a 71-year-old with mild left hemiplegia and acute fluent aphasia as a consequence of a right temporoparietal lesion [9]. In the context of normal calculation, praxis, memory and attention the authors suggested that AT results from the lesion to the inferior parietal lobe of the language dominant hemisphere. This group also noted that the deficit was only found when the patient was requested to retrieve a conscious representation of a spatial model of the body.

Denburg and Tranel noted in 2003 that there is a “. . . marked paucity of theoretical frameworks within which the concept of body schema could be properly situated and interpreted. . .” (pg., 172) [7]. Recently sequential and comprehensive normative psychometric and qualitative studies have begun and three distinct triply dissociated types of body representations have been identified by the PENN Cognitive Neurology group. The *body schema* is a dynamic postural representation coding and combining sensory afference and motor efference inputs/outputs and is largely automatic and nonconscious. The *body structural description* is an invariant coding of topological point-to-point configural maps specifying possible body part angles and relationships and has a strong spatial component although spatial problems per se cannot account for the disorder. Finally there is a linguistic element, the *body image*, which incorporates body part names, functions, and common associations with objects and/or tools and is verbal, conscious and lexicosemantic in nature [3,6,22].

Coslett and Schwobel distinguished between the body schema, body structural description and the body image [22]. Body schema tasks were exemplified by hand imagery and action tasks [23] as well as hand laterality tasks [17]. Body structural description tasks included localization of isolated body parts; localization of tactile input; and matching of body parts by location. Body image tasks included matching body parts by function and matching of body parts to clothing and objects. Using the largest consecutive and unselected stroke patient group of its kind the PENN lab found that the linguistic body structural description and body image tasks were associated with left temporal lesions whereas automatic on-line body schema tasks were associated with dorsolateral prefrontal and superior parietal lesions [22].

Downing’s MIT group discovered a region within the right lateral occipitotemporal cortex or the extrastriate body area (EBA) in 2001 that is selectively sensitive to whole human body parts compared to a range of other stimuli [10]. However, their task was nonverbal in contrast to this study’s verbal task and did not involve location of parts with a full figure model. There appears to be a strong rationale for using complete human figures since it has both face and ecological validity in comparison with previous part-based and nonverbal perceptual tasks. Reed and Farah found in 1995 that when participants imitated a real human actor’s poses proprioceptive information concerning their own

body position facilitated visuospatial perception of the model’s body positions [20]. The effects could not be attributed to a strategy or non-body based generalized spatial schema. Secondly the ‘inversion effect’ commonly held to index the modularity of the ‘face processor’ [24] has also been demonstrated for human figures whereas biomechanically implausible postures with body parts juxtaposed upon each other attenuated this body-inversion effect [21].

These inversion effects imply a specific neural module for the detection, recognition, identification of full human figures in addition to faces. The hypothesis of this experiment was that subjects successfully performing a body schema task in conjunction with verbalizable naming would demonstrate activation centered within the left parietal lobule compared to the control face processing tasks.

Nine right-handed subjects (four females, five males) of mean age 27 (S.D. = 9) participated in a single 20-min fMRI session. All subjects provided their written informed consent and the experiment was provided with institutional ethics approval under an experimental fMRI protocol. Five conditions included visual fixation (VF), face encoding (FE), face recognition (FR), and body part naming (BPN) and motor decision (MD). Stimuli were presented continuously at the rate of one item every 5 s and FE, FR, BPN, MD consisted of eight items in each of four 40 s blocks for a total of 128 experimental events. Four 40-s VF trials were also included as the baseline condition. FE and FR conditions were always run consecutively and the BPN, MD and VF blocks were run pseudorandomly. Accuracy and reaction time was measured with fiber optic response boxes [MRA Inc.: <http://www.mra1.com>] and recorded by Superlab Pro [Cedrus: <http://www.superlab.com>]. Images were back projected onto a wide angle field (60 cm wide × 50 cm height) blank screen at the front of scanner and visualized with a periscope mirror.

There were 32 single nonfamous FE stimuli placed amidst two isoluminant mosaics and there were 32 exemplars of familiar nonfamous FR stimuli placed amidst two novel not previously seen nonfamous distractor faces. There were also 32 instances of MD items and 32 different BPN items covering the entire body. With the BPN items both the left and right sides of the body were proportionally represented at randomly presented locations. All FE, FR, BPN and MD individual items were placed randomly in one of three lateralized positions arranged from left to right and these item by location instances were randomized across subjects such that hemifield of presentation was systematically controlled for (see Fig. 1).

FE and FR items were constructed from college yearbook photos and were included as loose task comparisons to check the accuracy and veracity of the functional neuroimaging paradigm using an entirely novel BPN task [4]. Each FE item was placed randomly in one of the three columns aligned left to right with two isoluminant mosaics constructed from the photos. The FE task required subjects to make a binary decision to the effect of “Press button 1 if the face is male and press button 2 if the face is female” [1]. In the FR task one of the 32 previously viewed target faces was placed randomly amidst two not previously viewed novel distractor faces. Subjects were prompted ‘Which face is familiar?’ requiring a three choice motor response

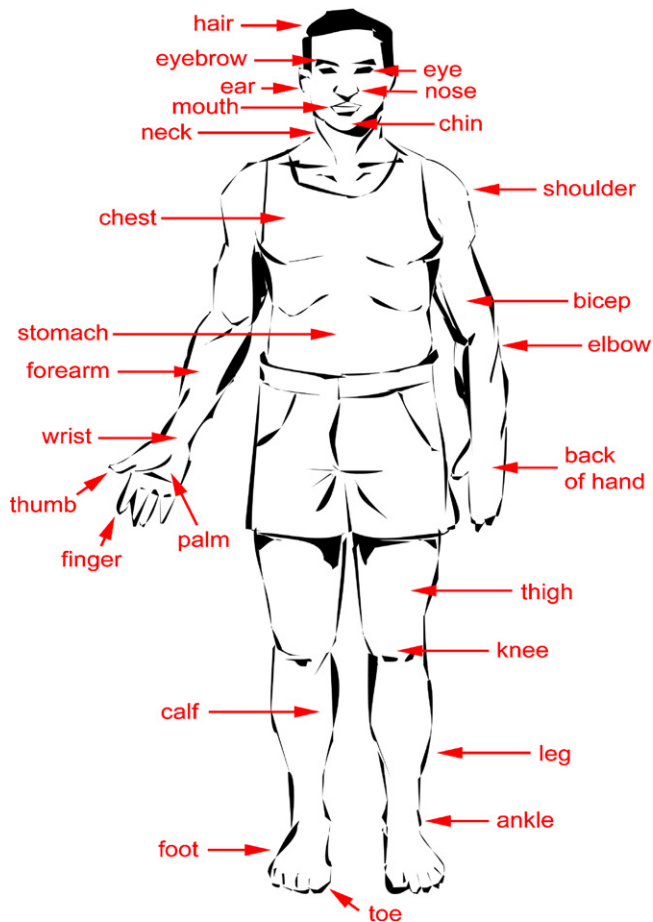


Fig. 1. Depiction of high-resolution anatomic black and white line drawing of human male figure with red arrows pointing towards separable body parts. Note that for the body part naming task three numbered figures were aligned from left to right and each figure had one red arrow pointing to one body part. Subjects then choose the human figure whose red arrow pointed to the named target body part with a three choice response button press ($N = 32$ items in total). Note that some body parts are not depicted in the illustrative picture for the sake of clarity of presentation.

similar to the BPN tasks. Subjects provided a response with their dominant right hand which required a two choice decision in the FE condition and a three choice decision in the FR, BPN and control MD tasks. For the control motor decision (MD) task one of the three isoluminant mosaics was highlighted by a red arrow and the subject was asked verbally to 'Press the button for the indicated mosaic' (Fig. 2).

The experiment was run on a 1.5 T Siemen's Sonata MRI scanner and 30 oblique gradient-echo fast echo planar sequence derived slices were obtained ($TR = 5$ s, $TE = 50$ ms, 4 mm thick, $gap = 0$ mm) covering the entire brain. Functional images were realigned to the first volume to account for subject motion and normalized to MNI space using Statistical Parametric Mapping Version 2: [<http://www.fil.ion.ucl.ac.uk/spm>]. The data was smoothed with a Gaussian kernel (8 mm full-width half-maximum) and checked for group differences in global signal and z -scaled. The statistical significance and spatial extent of clusters of activation were evaluated with a peak height threshold ($p < 10^{-4}$) and a spatial extent threshold of 19 contiguous

voxels [1]. SPM99's MNI brain template coordinates were converted into Talairach atlas space for determination of regions of interest. Statistical thresholding values were corrected for multiple comparisons across the whole brain.

The three experimental tasks of FE, FR and BPN were subtracted from both the VF and the MD task reference images however only the (experimental task – motor decision) results are presented here for purposes of brevity. The pattern of neuronal network activation for the FE and FR tasks are both highly consistent with activation patterns in previous functional neuroimaging experiments using identical tasks [5] as well as with critical foci that would be expected on the basis of neuropsychological lesion studies [2]—see Table 1. These findings suggest that the loose task comparisons [4] of FE and FR and experimental fMRI protocol first initiated at the University of Alberta in 2001 was accurate and precise in delineating the putative body part naming task activations.

BPN activated the left occipitotemporal lobe in the vicinity of the rostral fusiform gyrus or extrastriate cortex, the left medial superior parietal lobe or precuneus, the left middle frontal gyrus, the right precentral gyrus, the right superior frontal gyrus and the right cerebellum (all p 's < 0.0001). A region of interest analysis was undertaken within the left parietal lobe. ANOVA of percent signal change from motor decision revealed a highly significant main effect of groups [$F(3, 32) = 13.4$, $p < 0.0001$]. This volume of interest consisted of a median of 615 voxels across subjects. Planned orthogonal contrasts demonstrated that BPN had greater signal change within the VOI compared to FE ($p < 0.001$) and FR ($p = 0.01$). The Talairach coordinates of the center of mass of this volume of interest was within the left medial superior parietal lobe [$x = -20$, $y = -62$, $z = 50$]. Significant activation within the left medial superior parietal region of interest was observed within all nine male and female subjects. Behavioral response accuracy levels were uniformly high across all conditions (mean $\geq 95\%$) and subjects indicated no associated difficulties with task performance. Statistical comparison of reaction times revealed that the crucial comparison of BPN was not significantly different from FR suggesting that these two tasks were of equivalent difficulty ($p > 0.50$) (Table 2).

In this experiment in contrast to Downing et al's study activation within the right extrastriate body area (EBA) was not found [10]. These investigators found robust activation within the right lateral occipitotemporal cortex (EBA) with pictures, line drawings, stick figures, and/or silhouettes of full human figures as stimuli compared to many other animate and inanimate full object classes. We did find however left occipitotemporal activations (albeit this more medial, rostral and inferior) than did Downing et al. perhaps as a function of the verbal, pictorial, conceptual and categorical nature of our task [19]. That is the task used in this study required conceptually based manipulation of the full body schema within the context of coordination with stored knowledge about the names and locations of verbally named body parts.

Bilateral activation of the frontal lobes in conjunction with the left superior parietal activation is consonant with the on-line spatial transformation of the body schema rather than the posited more inferior parietal activation associated with the body

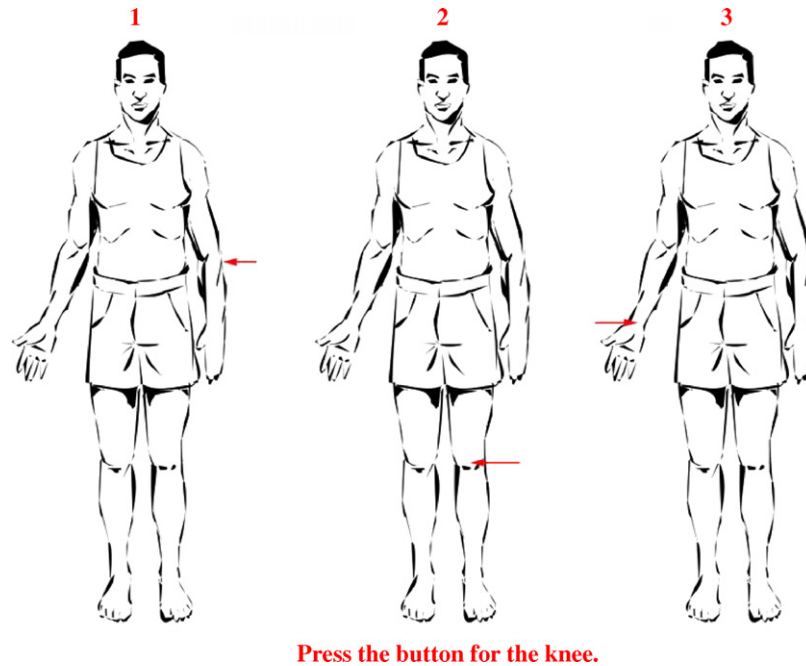


Fig. 2. One highlighted body part was depicted on each of three separate identical human figures aligned in three columns from left to right. Each human figure was labeled 1–3 from left to right and each figure had only one red arrow pointing to a specific body part (e.g., knee, elbow, wrist). Subjects were prompted with a question at the bottom of the screen “Press the button for the [body part]” requiring a three choice motor response similar to the face recognition task with two associated randomly placed isoluminant mosaics.

structural description. The long reaction times associated with the body part naming task compared with the face tasks suggests that on-line manipulation and alignment of the body schema of individuals with the mirror-image human figure occurred

[3,6,17,22,23]. Left superior and medial parietal and right cerebellar activation suggests that verbal mediation of learned body parts names in alignment with self-generated body-centered schema maps was operative in the task used in this study. In

Table 1
Regions demonstrating significant activations during face encoding (FE), face recognition (FR) and body part naming (BPN) subtracted from the activation from the sensorimotor activation control or motor decisions (MD) task ($Z_{\text{critical}} = 4.00$, $p < 0.0001$; height threshold $Z = 3.00$ or $p < 0.001$)

Brain region	Number of voxels	Brodmann's area	Talairach coordinates			Z score
			x	y	z	
Body part naming						
L occipitotemporal lobe (fusiform gyrus)	905	37	-48	-40	-15	4.29
L parietal lobe (precuneus)	615	7	-20	-62	50	4.53
L middle frontal gyrus	325	9	-50	8	38	4.43
R frontal lobe (precentral gyrus)	325	6	50	4	36	4.46
R superior frontal gyrus	130	6	26	-8	72	4.07
R cerebellum	786	-	40	-60	-24	5.30
Face encoding						
L insula	258	13	-32	22	0	4.62
L parahippocampal gyrus	50	19	-34	-40	-4	4.18
L claustrum	36	-	-24	2	22	4.04
R parietal lobe (precuneus)	63	7	24	-66	30	4.41
R temporal lobe (fusiform gyrus)	29	36	40	-36	-22	4.32
R hippocampus	19	-	32	-26	-10	4.06
Face recognition						
L fusiform gyrus	633	19	-38	-66	-12	4.11
L occipital lobe (cuneus)	101	18	-22	-98	-2	4.03
L cerebellum	701	-	-4	-72	-28	4.78
L anterior cingulate	180	24	-2	2	28	4.00
R anterior cingulate		33	6	12	22	4.25
R superior parietal lobe	341	7	30	-74	44	4.72
R inferior frontal gyrus	203	9	54	10	32	4.17
R cerebellum	1551	-	42	-60	-24	4.80

Table 2
Reaction time and percent signal change in the left medial superior parietal lobe between conditions

Visual fixation	Face encoding (S.D.)	Face recognition (S.D.)	Body part naming (S.D.)
No response (ms)	1510 (230)	2110 (260)	2200 (270)
100% baseline	37% (11)	75% (40)	151% (70)

Note that the critical face recognition and body part naming conditions were of equivalent difficulty ($p > 0.50$).

addition verbal reports after the experiment revealed that subjects used the mirror-image full human figure to visually locate and identify body part names from memory.

Buxbaum et al. found that the nonconscious body schema likely plays a significant role in the dynamic interactive praxis system which provides “top-down: support to spatiomotor procedures computed on-line” [3]. Additionally cases of subjects with congenitally absent limbs with early onset phantoms strongly imply a genetic basis for the mental representation of body shapes [14–16]. Many current functional neuroimaging studies of the body schema use tasks that are not realistic and involve no spatial transposition or linguistic element unlike ecologically valid examples of such tasks. This is in stark contrast to the older more ecologically valid neuropsychological tasks (e.g., pointing to a body part on a manikin or full-size drawing of a human figure) used in the classic lesion literature.

A robust left medial superior parietal region in conjunction with bilateral frontal and left inferior occipitotemporal network of activation was found in all subjects when matching a body part to a human figure. These findings suggest that ecologically valid verbal body schema tasks requiring both localization and identification require superior parietal–dorsolateral prefrontal coordination of the self-generated body schema as well as categorical semantic access instantiated by the left rostral occipitotemporal image-based recognition systems, respectively [19]. There was no left inferior parietal; posterior perisylvian; or receptive language-related Wernicke’s area related activation in this study associated with the body part naming task.

This lack of an activation of language or praxis related areas often associated with the left inferior parietal regions likely occurred for two reasons. First of all the similar verbal and praxis components of the control motor decision and body part naming tasks resulted in a subtraction and nullifying of any purely receptive language-related activation and/or usual step-wise praxis associated with the left inferior parietal lobule. Secondly the greater emphasis on the spatial transposition of named body parts across the pictorial representation of the entire human figure high-resolution line drawing accentuated the localization and on-line transformation of the mirror-image figure associated with the automatic body schema representation computed in BA 5 and 7.

Acknowledgements

Simon M. McCrea, PhD was supported by a National Sciences and Engineering Research Council of Canada (NSERC)

grant #241750 while a post-doctoral fellow at the Department of Biomedical Engineering at the University of Alberta, Canada. This research was presented in part at the *Annual Meeting of the Cognitive Neuroscience Society* in 2005 in New York. Prin X. Amorapanth of Cognitive Neurology at the University of Pennsylvania kindly provided the illustration. This study was completed in the fall of 2001 at the University of Alberta.

References

- [1] Andreasen NC, O’Leary DS, Arndt S, Cizadlo T, Hurtig R, Rezai K, et al. Neural substrates of facial recognition. *J Neuropsychiatry Clin Neurosci* 1996;8:139–46.
- [2] Bauer RM, Demery JA. Agnosia. In: Heilman KM, Valenstein E, editors. *Clinical neuropsychology*. 4th ed. New York: Oxford University Press; 2003. p. 236–95.
- [3] Buxbaum LJ, Giovannetti T, Libon D. The role of the dynamic body schema in praxis: evidence from primary progressive apraxia. *Brain Cogn* 2000;44:166–91.
- [4] Cabeza R, Kingstone A. *Handbook of functional neuroimaging*. 2nd ed. Cambridge, MA: MIT Press; 2006.
- [5] Cabeza R, Nyberg L. Imaging cognition II: an empirical review of 275 PET and fMRI studies. *J Cogn Neurosci* 2000;12:1–47.
- [6] Coslett HB, Saffran EM, Schwoebel J. Knowledge of the human body: a distinct semantic domain. *Neurology* 2002;59:357–63.
- [7] Denburg NL, Tranel D. Acalculia and disturbances of the body schema. In: Heilman KM, Valenstein E, editors. *Clinical neuropsychology*. 4th ed. New York: Oxford University Press; 2003. p. 172–84.
- [8] Denes G. Disorders of body awareness and body knowledge. In: Denes G, Pizzamiglio L, editors. *Handbook of clinical and experimental neuropsychology*. East Sussex, UK: Psychology Press; 1999. p. 497–506.
- [9] Denes G, Cappelletti JY, Zilli T, Dalla Porta F, Gallana A. A category-specific deficit of spatial representation: the case of autotopagnosia. *Neuropsychologia* 2000;38:345–50.
- [10] Downing PE, Jiang Y, Shuman M, Kanwisher N. A cortical area selective for visual processing of the human body. *Science* 2001;293:2470–3.
- [11] Gerstmann J. Fingeragnosie: Cine umschriebene Störung der Orientierung am eigenen Körper. *Wien Klin Wochenschr* 1924;37:1010–2.
- [12] Goldenberg G. Disorders of body perception. In: Farah MJ, Feinberg TE, editors. *Patient-based approaches to cognitive neuroscience*. Cambridge, MA: The MIT Press; 2000. p. 107–14.
- [13] Goldenberg G. Disorders of body perception and representation. In: Feinberg TE, Farah MJ, editors. *Behavioral neurology and neuropsychology*. 2nd ed. New York: McGraw-Hill; 2003. p. 285–94.
- [14] Melzack R. Phantom limbs, the self and the brain—the D.O. Hebb memorial lecture. *Can Psychol* 1989;30:1–16.
- [15] Melzack R. Phantom limbs and the concept of a neuromatrix. *Trends Neurosci* 1990;13:88–92.
- [16] Melzack R, Israel R, Lacroix R, Schultz G. Phantom limbs in people with congenital limb deficiency or amputation in early childhood. *Brain* 1997;120:1603–20.
- [17] Parsons LM, Fox PT, Downs JH, Glass T, Hirsch TB, Martin CC, et al. Use of implicit motor imagery for visual shape discrimination as revealed by PET. *Nature* 1995;375:54–9.
- [18] Pick A. Zur Symptomatologie des atrophischen Hinterhauptslappens. In: *Arbeiten aus der deutschen psychiatriischen Universitätsklinik in Prag*. Berlin: Karger; 1908.
- [19] Price CJ, Noppeney U, Phillips J, Devlin JT. How is the fusiform gyrus related to category-specificity? *Cogn Neuropsychol* 2003;20:561–74.
- [20] Reed CL, Farah MJ. The psychological reality of the body schema: a test with normal participants. *J Exp Psychol Hum Percept Perform* 1995;21:334–43.

- [21] Reed CL, Stone VE, Bozova S, Tanaka J. The body-inversion effect. *Psychol Sci* 2003;14:302–8.
- [22] Schwoebel J, Coslett HB. Evidence for multiple, distinct representations of the human body. *J Cogn Neurosci* 2005;17:543–53.
- [23] Sirigu A, Duhamel JR, Cohen L, Pillo B, Dubois B, Agid Y. The mental representation of hand movements after parietal cortex damage. *Science* 1996;273:1564–8.
- [24] Yin RK. Looking at upside-down faces. *J Exp Psychol* 1969;81:141–5.